

# OPTIMIZING VAP-SCARS AFTER CHILDHOOD CANCER TREATMENT

CMA de Bruijn<sup>1,\*</sup>, FW Hoff<sup>1,\*</sup>, AML Peek<sup>1</sup>, MM Bruggeman-Westermann<sup>2</sup>, TH van Dijk<sup>3</sup>, JB Terra<sup>4</sup>, ESJM de Bont<sup>1</sup>

<sup>1</sup>Beatrix Children's Hospital, University Medical Centre Groningen, Department of Paediatric Oncology, University of Groningen, Groningen, The Netherlands; <sup>2</sup>Practise for Colour Meridian Therapy, Groningen, The Netherlands; <sup>3</sup>University Medical Centre Groningen, Department of Dermatology, Groningen, University of Groningen, The Netherlands;

<sup>4</sup>University Medical Centre Groningen, Department of Paediatric Surgery, Groningen, University of Groningen, The Netherlands.

\*Both authors contributed equally



umcg a.m.l.peek@umcg.nl

## Background/Objectives

Majority of the pediatric cancer patients are treated with chemotherapy using Venous Access Ports (VAP). However, after surgical removal of the VAP often prominent scars remain, which can be quite debilitating for patients. Due to lack of standardized care for VAP-scars, the aim of this study was to determine the efficacy of two different treatments for optimal healing of VAP-scars, respectively Dermatrix<sup>®</sup> silicone gel and Meridian Colour Therapy (a treatment with silk patches, dyed by natural pigments).

Instructions were given to patients at the start of (both) treatments and patients were self-sufficient in applying the treatment.

## Study design

- Pilot study, empirical collection of data, no randomisation. Data collection March 2014 – March 2016.
- Patients/parents had the option to chose scar-care: Dermatrix<sup>®</sup> silicone gel, MCT or no additional treatment (Control).

## Patients & Methods

- 20 patients; 21 scars
- Light photographs of scars.
- POSAS scales (for scoring scar tissue); both patient and observer (by 2 independent dermatologists) . A lower score indicates better scar-healing.
- Time points. Before VAP removal and 3, 6 and 12 months after VAP removal (T3, T6, T12).
- Both photographs and POSAS scores were obtained for each scar, at each time point.
- Statistical analysis . Mann-Whitney-U-tests.

Control n = 6  
Dermatrix n = 7  
MCT n = 8

Figure 1. Light photographs of VAP scars

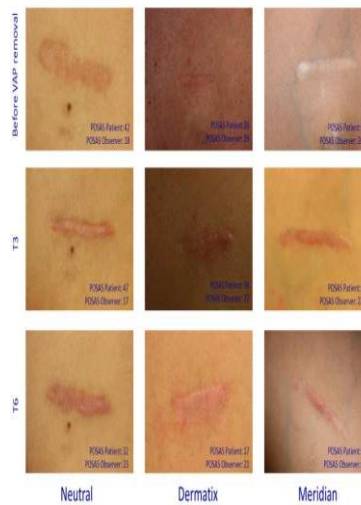
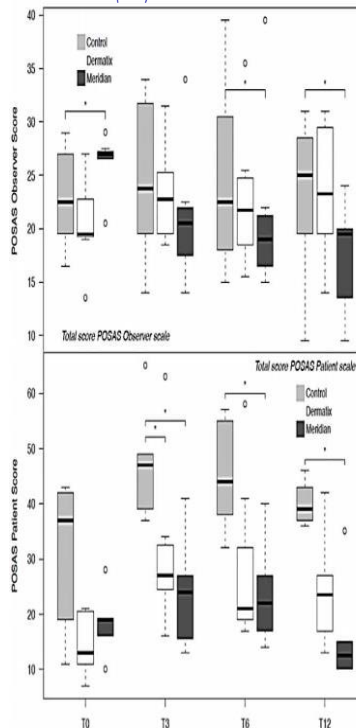


Figure 2. Scars assessment prior to and 3, 6 and 12 months after VAP-removal using the POSAS patient scale (upper) and the POSAS observer scale (lower).

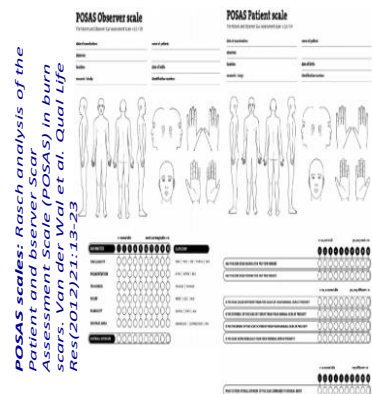


## Results

- Prior to VAP-removal, observers scored the scar tissue of patients in the MCT group significantly worse (higher POSAS score) compared to scars with no treatment (P=0.007).
- At 3 months Patient POSAS scores of control scars were higher than Dermatrix and MCT scars; p=0.022 (not observer POSAS scores).
- At 6 and 12 months this difference in scores was still seen (so lower PASAS score for Dermatrix and MCT scars), but was only significant in the MCT-group (P=0.010 for both POSAS-patient and POSAS-observer).

## Conclusion

Meridian Colour Therapy showed better results in scar healing during the first year after VAP-removal, compared to no additional treatment. MCT could be used for optimizing the healing of scars after surgical VAP-removal in pediatric cancer patients. This treatment can be done at home, after adequate instruction.



POSAS scales: Rasch analysis of the Patient and Observer Scar Assessment Scale (POSAS) in burn scars. Van der Wal et al. Qual Life Res (2012) 21: 13-23